

*Congenital melanocytic nevus/Plexiform neurofibroma.* 172

*Juvenile pleomorphic adenoma of buccal salivary glands.* 175

*Infantile hemangioma treated with atenolol.* 179

*Lipoatrophic panniculitis.* 182

*Idiopathic plasma cell balanitis of Zoon.* 189

*Childhood bullous pemphigoid.* 193

*Balanitis xerotica obliterans in twins.* 197

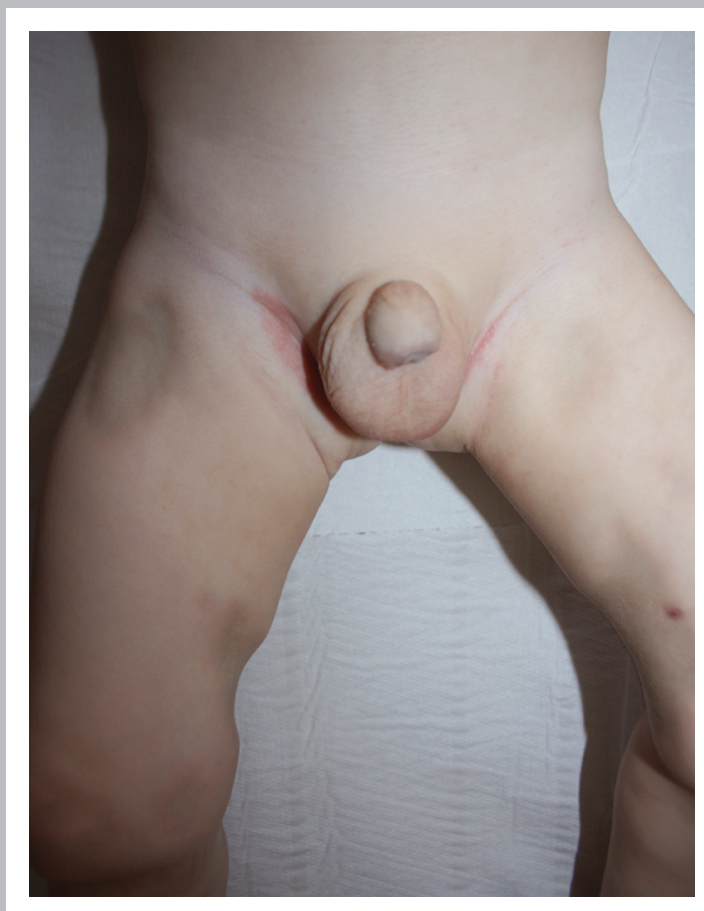
*Infantile acropustulosis. A late diagnosis.* 201

*Incontinentia pigmenti. 3 family trees.* 204

*Late onset acrodermatitis enteropathica.* 211

*Encephalocele.* 212

*Acquired port-wine stain.* 213



*Late diagnosis of hemangioma.* 214

*Propranolol and ulcerated vulvar hemangioma.* 215

*Non involuting congenital hemangioma.* 216

*Two baby girls with PHACE syndrome treated with propranolol.* 218

*Congenital hamartoma of the arrector pili muscle.* 220

*Atypical segmental vitiligo. Late diagnosis.* 221

*Skin lesions due to human bite.* 222

*Actinic comedonal plaque.* 223

*Early topical propranolol is more effective.* 224

*Juvenile xanthogranuloma regresses more rapidly than hemangioma.* 225

*Herpes-like eruption due to imiquimod.* 226