

Keratosis pilaris / Multiple trichoepitheliomas. 132

Evaluating PRISM as a measure of life quality for children with skin diseases. 135

Subcutaneous fat necrosis in two newborns treated with induced hypothermia. 143

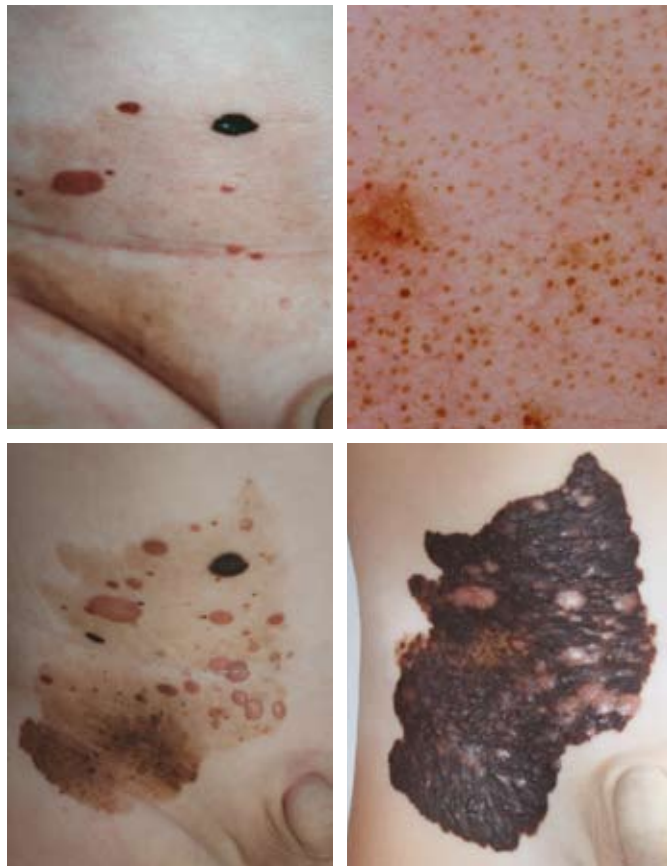
Familial reactive perforating collagenosis. 147

Possible role of group A β -hemolytic Streptococcus in Gianotti-Crosti syndrome. 151

Congenital atrophoderma of Pasini and Pierini. 154

Generalized eruptive histiocytoma. 157

Hand care in epidermolysis bullosa. 160



Clinical and dermoscopic findings in 58 cases of nevus spilus. 165

Ulcers due to subcutaneous injection of medical ozone. 183

Neonatal striped hyperpigmentation of the torso secondary to split lines of the horny layer at birth. 184

Lichen sclerosus of the vulva in an 8-year-old girl. 186

Benign fibrous histiocytoma in a 7-year-old boy. 187

Jessner's lymphocytic infiltration of the skin in three siblings. 188

Multiple trichoepitheliomas. 190

Pityriasis versicolor in two 8-year-old monozygotic twins. 192