

Neonatal varicella. A case report.

Patrizi A., Rinaldi R., Savoia F., Neri I., Bardazzi F.
Department of Specialistic and Experimental Clinical Medicine
Division of Dermatology, University of Bologna, Bologna (Italy)

Neonatal varicella is a rare disease, because 90-95% of women have developed specific antibodies against the varicella-zoster virus (VZV) by the time they enter childbearing age (2, 7). The term neonatal varicella refers to a chickenpox that occurs in the first 2 weeks of life in the newborn and during the last 3 weeks of pregnancy or within the first 10 days after delivery in the mother (4). We report here the case of a newborn, who presented neonatal varicella on his second day of life.

Case report. A 2-days old male baby, born at term after a normal pregnancy, was visited because of a cutaneous rash characterized by erythematous macules, sometimes surmounted by vesicles and pustules, located to both upper and lower arms and to the trunk (Fig. 1). The baby presented mild fever (38.8°C). The physical examination was otherwise normal.

The mother referred that, 9 days before the delivery, she presented a few cutaneous lesions similar to those of her son, with mild fever. Vaginal examination excluded a genital herpes.

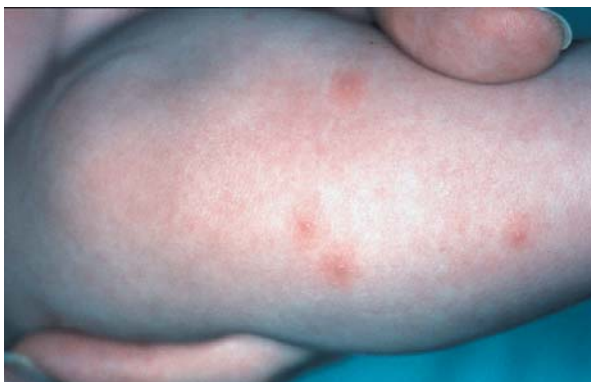


Fig. 1: Vesiculo-pustular lesions on the right leg.

Tzanck smear from a vesicle of the baby showed multinucleated giant cells leading to the diagnosis of neonatal varicella, that was subsequently confirmed by serologic tests against VZV. The infection was transplacentally transmitted, because the mother had developed varicella in the last days of pregnancy. Intravenous acyclovir, 30 mg/kg/die in 3 divided doses, for 7 days, was given, with complete clinical healing of his lesion.

Discussion. Neonatal varicella is in most cases due to maternal varicella occurring in the last 3 weeks of gestation (8). The incubation period for varicella is 10-21 days. Therefore, varicella is called neonatal or perinatal when the infant shows the disease within the 10th-12th day of life. In this case VZV is acquired transplacentally. After the 10th-12th day of life the disease is considered acquired by postnatal infection.

The prognosis of neonatal varicella is variable. When the mother's rash occurs between 4-5 days before the delivery and 2 days after the delivery, neonatal varicella is usually severe, because the newborn is infected by a large inoculum of virus, without the protection of maternal IgG antibodies. On the other hand, when the mother's rash occurs 5 or more days before delivery, neonatal varicella is usually mild, due to IgG antibodies crossing the placenta (5). Considering the age of the newborn, neonatal varicella is usually mild when the rash occurs in a baby within the first 4-5 days of life, while the disease is severe when occurring between the 5th and the 12th day of life. Acquired postnatal varicella may also be severe (2).

The severe forms of neonatal varicella, besides the classical rash characterized by vesicles,

pustules and crusts on an erythematous background, may also present a multisystem involvement (lung, liver, central nervous system), with high mortality, up to 20-30% of the cases, if the antiviral treatment is not performed (5, 8).

Clinical diagnosis may be confirmed by Tzanck smear (although the latter does not allow to distinguish between the infections from different herpes viruses), which shows multinucleated giant cells, direct immunofluorescence or polymerase chain reaction on vesicle material (after scraping), viral culture from cutaneous lesions and evaluation of IgM and IgG antibodies in the newborn's serum.

Antiviral therapy with intravenous acyclovir, 10-20 mg/Kg every 8 hours, for 5-7 days, is recommended for all the cases of neonatal varicella occurring in the first 2 weeks of life (6).

A profilactic therapy may be done with intramuscular anti-VZV immune globulins (VZIG), 250 mg in a single dose, within 72 hours from the exposure to the VZV (1, 6). VZIG do not completely protect the baby from the infection. Therefore varicella may anyway occur despite their use, even though in a less severe form and after a longer incubation period. Hanngren and colleagues in 1984 stated that the rate of severe varicella despite the correct use of VZIG in newborns significantly exposed to the VZV is about 5% (3). Patients treated with VZIG must be observed, even though not necessarily in hospital, and acyclovir treatment must be considered in infants that develop the disease. VZIG are not useful when varicella is already evident (1, 7).

There are four indications for the use of VZIG (1, 2) as follows:

- immunocompromised children after significant exposure to the VZV;
- newborns of mothers who developed varicella in the period between 5 days before delivery and 2 days after delivery;
- premature infants less than 28 week's gestation or very low birth weight infants, after significant exposure to the VZV, regardless of maternal history for varicella;
- premature infants with a maternal history negative for varicella or without maternal antibodies against VZV, after significant exposure.

It is important to remember that varicella is an extremely contagious disease and therefore both the mother and the newborn must be isolated from other infants, to prevent new infections.

In conclusion, neonatal varicella, as neonatal herpes, is a potentially mortal disease and all the cases of vesicular and pustular eruptions in the neonatal period must be carefully evaluated, in order to make a correct and immediate diagnosis and therapy.

Address to:

Dr. Federico Bardazzi

Clinica Dermatologica

Via Massarenti 1 - 40138 Bologna (Italy)

e-mail: fbardazzi@orsola-malpighi.med.unibo.it

References

- 1) Center for Disease Control of Atlanta. Recommendations of the Immunization Practices Advisory Committee (ACIP) Varicella-Zoster Immune Globulin for the Prevention of Chickenpox. Disponibile presso il sito: <http://www.cdc.gov/mmwr/preview/mmwrhtml/00022690.htm>
- 2) Forrest J.M., Mego S., Burgess M.A. - Congenital and neonatal varicella in Australia. *J. Paediatr. Child Health* 36, 108-13, 2000.
- 3) Hanngren K., Grandien M., Granstrom G. - Effect of zoster immunoglobulin for varicella prophylaxis in the newborn. *Scand. J. Infect. Dis.* 17, 343-7, 1985.
- 4) Hurwitz S. - Cutaneous disorders of the newborn. In: Hurwitz Clinical Pediatric Dermatology. A textbook of skin disorders of childhood and adolescence. WB Saunders Company, 2nd Edition 1993; Philadelphia (USA): p. 25.
- 5) Isaacs D. - Neonatal chickenpox. *J. Paediatr. Child Health* 36, 76-7, 2000.
- 6) Kesson A.M., Grimwood K., Burgess M.A., et Al. - Acyclovir for the prevention and treatment of varicella zoster in children, adolescents and pregnancy. *J. Paediatr. Child Health* 32, 211-7, 1996.
- 7) McCrary M.L., Severson J., Tyring SK. - Varicella zoster virus. *J. Am. Acad. Dermatol.* 41, 1-14, 1999.
- 8) Sauerbrei A., Wutzler P. - Neonatal varicella. *J. Perinatol.* 21, 545-9, 2001.