

*Infantile segmental NF1 /
Hypermelanic nevus.* 132

*Self-healing juvenile cuta-
neous mucinosis.* 135

*Cutis verticis gyrata unveils
insulin resistance.* 141

*Multiple pilomatricomas
and partial trisomy 9.* 145

*Linear and whorled nevoid
hypermelanosis with neuro-
logical manifestations.* 148

*Aplasia cutis congenita and
coarctation of the aorta.* 153

*Telecare of infantile hema-
ngioma and COVID-19.* 157

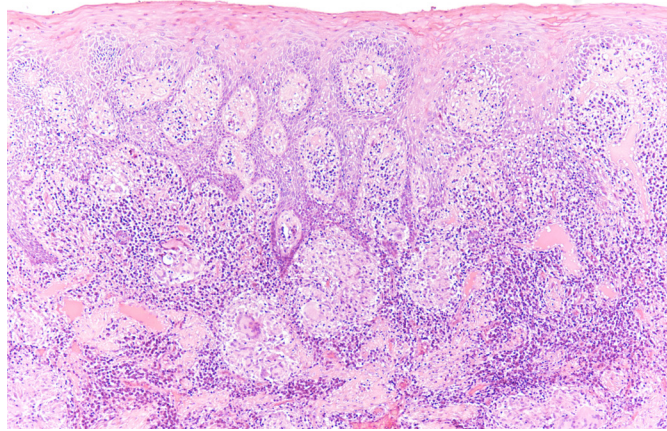
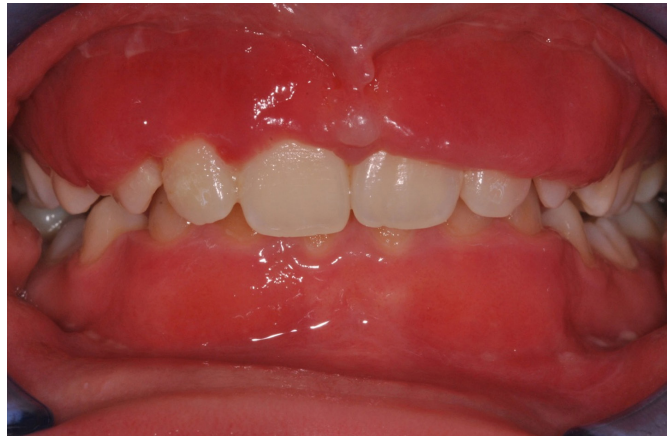*Childhood psoriasis and
serum calcium levels.* 161

*Angioma as a clue to the
diagnosis of xeroderma
pigmentosum.* 172

*Linear and whorled nevoid
hypermelanosis.* 174

*Melanogenesis of angio-
matoid Spitz nevus.* 175

*Tyson glands
hyperplasia.* 176



*Acute recurrent localized
glossitis.* 178

*Nodular acne infantum
and gonadorelin.* 179

Bilateral chalaziosis. 180

*Chalazion with cutaneous
horn.* 181

*Extra-genital lichen scler-
osus.* 182

*Congenital segmental li-
chen sclerosus et atrophie-
cus.* 183

*Infantile bullous pemphi-
goid healed with topical
treatment.* 184

*Orofacial granulomatosis
with severe gingival involv-
ement.* 186

*Granular parakeratosis or
acanthosis nigricans?* 188

Short anagen syndrome. 191

*Squamous cell carcinomas
in Congolese albino.* 192