

That kind of new rays.

Vardeu M.F.
Pediatrician, Cagliari, Italy

Summary

The therapy of tinea capitis was an important dermatological problem with severe psycho-social effects until the discovery of griseofulvin. Before that discovery physicians had realized that the only possible therapy was the total temporary hair removal and to achieve this they turned to chemical and physical methods used in cancer therapy, drawing inspiration from the side effects that the antimetabolic therapy produces on rapidly growing tissues as the epidermis and its adnexa. The Author, who discovered a movie of a century ago on radiation therapy performed to obtain a provisional epilation in the Cagliari (Italy) Institute of Radiotherapy, retraces the stages of the unbelievable success of radiotherapy carried out from 1910 to 1950 on about 200,000 children affected by ringworm belonging to disadvantaged classes in the old and new world.

Key words

Tinea capitis, radiation therapy, hair removal.

Ringworm of the scalp is a fungal infection caused by keratinophilic dermatophytes. Today it can be easily treated with antifungal agents, in particular with griseofulvin discovered in 1939. Before this discovery, although the specialists had realized that the transmissible agents of the disease (4) were localized in the patients' hair and scales, there was no effective remedy.

For this reason, the mycosis persisted endemic in the US and Europe; recurrent outbreaks occurred due to inadequate sanitation or contact and promiscuity with affected people or animals in degraded social environments and in schools, typically in prepubertal age. The head lesions were very obvious, unsightly, smelly and contagious; this was why the child affected by ringworm was sidelined with serious psychological consequences and was considered a problem for the whole community.

Before the discovery of griseofulvin the topical therapy was able to cure mycotic infections involving the keratin of the surface epidermis; on the other hand, when the infection spread to the hair keratin there was no topical treatment able to reach the hair bulb located in the deep dermis. Physicians had then realized that the only remedy to cure tinea capitis was to remove the hairs from their roots.

The radical removal of the hair was obtained by physical or chemical methods. Physical methods consisted in tearing the hair with the hands, using forceps or resin, flour and pitch caps to keep on the head for a while and then pull vigorously with unbearable pain for the child and sometimes scarring alopecia (15).

The chemical methods were apparently less traumatic but charged with severe side effects because they were based on the use of antimetabolic agents such as thallium salts (4, 7).

Before being used for epilation in case of ringworm of the scalp thallium acetate was really used in patients with advanced malignancies because the thallium was in the periodic scale near the lead, that had shown some efficacy as an anticancer drug; its antimitotic activity was evident as a side effect also on the rapidly dividing tissues and thus also on the hair making them fall; hence its use in the epilation.

The treatment consisted in the administration of thallium acetate in a single dose of 8mg / kg by mouth in water and sugar (7); the drug had to be freshly prepared and pure and the child had to stay in bed during treatment. The hair began to fall on the seventh day and the fall was complete in 19 days. Infected hair resisted a few more days than healthy ones; regrowth was heralded by numerous exclamation mark shaped hair.

Side effects were observed in 25% of cases after the 7th day of taking thallium and consisted of pain in the legs, loss of appetite, and headache; the pains of the lower limbs were more tolerable when the child was in bed, and ceased with the complete hair loss.

When Conrad Roentgen discovered the X-ray the observation of hair loss in patients undergoing radiation therapy gave rise to the hope of a new and definitive technique to practice quick and painless therapeutic alopecia. More than one hundred clinical cases of patients healed successfully from ringworm with the radio-electrical method, which initially consisted of a single powerful irradiation, were presented in January 1904 at the French Society of Dermatology by Raymond Sabouraud, who published in the same month his experience in the *Annals of the Pasteur Institute* (19, 20, 21).

The new technique was immediately applied with excellent results to the students of the School for Children with ringworm attached to Hospital Saint Louis in Paris and a few months later at Charing Cross Hospital and Victoria Hospital for children in London. The Londoners Authors noted that with the first rudimentary machines it was not always possible to exactly dose the power of radiation emitted and reported the short-term side effects of X-rays such as erythema and burning of the treated areas leading ultimately to final scarring alopecia.

The failures and side effects were attributed to the characteristics of the instruments used, the inexperience of the operators, the lack of cooperation of children and difficult to standardize therapeutic method, the results of which could also vary with changes in the weather conditions. The high temperature of the irradiated area led to suspect possible damage to the CNS and suggested in 1905 the proposal to treat only children over the age of three years, with well-ossified cranial sutures (13, 14).

In May 1909 Adamson (1), who was a dermatologist of Saint Bartholomew's Hospital in London, in the *Lancet* suggested and illustrated in detail with pictures and drawings the method for the treatment of ringworm, experienced recently by Kienbock in Vienna in just a few cases of *tinea capitis*. The following year, the same method was decidedly echoed by Sabouraud in his treatise *Les Tignes*, a learned treatise on mycosis, probably in order to resolve disputes and the concerns raised by the new therapy in the international scientific community.

Some serious accidents caused by radiation or by operator errors were considered by Sabouraud small in relation to the speed of healing - three months instead of two years - the lowering of treatment costs, hospitalization times and number of hospitalizations, the possibility to have available in the hospital spaces previously occupied by children with ringworm, the disappearance of entire colonies of patients with ringworm from the city banlieue (19).

In the following years, in spite of the mentioned side effects (2), the irradiation of the head with X-ray continued to be carried out around the world, especially in economically depressed countries and needy populations due to war, famine and immigration, or persecuted for racial reasons as it was in the early 1900s for the Jewish populations in Europe, where the diseases due to poverty such as ringworm and trachoma were more frequent were (23).

In those years in order to eradicate the disease and provide the population with preventive hygiene notions some dedicated non-governmental organizations created networks of assistance and information and stimulated the implementation of massive radiation therapy to treat ringworm in

tens of thousands of Jewish individuals, mostly children (23).

In Sardinia (Italy) the Institute of Radiotherapy belonging to the Cagliari Dermatology and Syphilology Department, set up in 1914 with aid from the Public Instruction Ministry and Hospital Administration and directed by Francesco Radaeli, in the first year of operation made some thousands of applications with Roentgen rays and radium to cure diseases like lupus, verrucous TBC, scrofulous and leprosy nodules, birthmarks, skin and mucous epitheliomas, ringworm and onychomycosis; the radiation treatment was praised by the local press (11) as an effective, painless and viable in the clinic therapy. In the '30s the Institute of Cagliari was greatly expanded and

treatment with radiation therapy for ringworm and other fungal infections was extended to the people, to groups of affiliated workers, the urban poor and children with tinea capitis coming from particularly poor areas of the island, as was the Province of Nuoro (26).

For the treatment of ringworm of the scalp hair removal was obtained with the Kienbock method; by means of a cruise (Fig. 1) five equally spaced points were fixed on the head; the tube was then centered on each of the five points and the scalp was irradiated on five partially overlapping fields (Fig. 2); after 15-17 days, the hair could be removed with a slight traction (Fig. 3); a complete alopecia was then obtained (Fig. 4) which lasted about two months; during that period keratolytic




Fig. 1

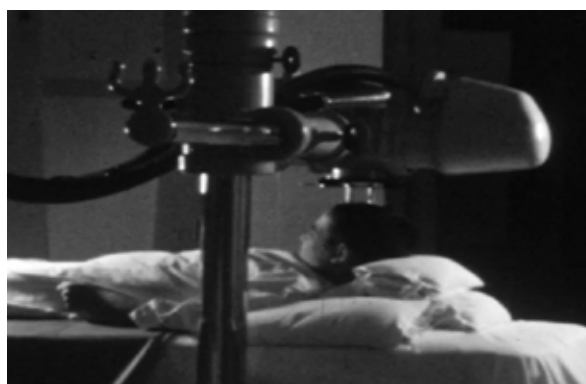

Fig. 2

Fig. 1, 2: The cruise (Fig. 1) used in the Cagliari Radiotherapy Institute to establish 5 equidistant points of the scalp to be irradiated; in Fig. 2 a child with ringworm during irradiation.

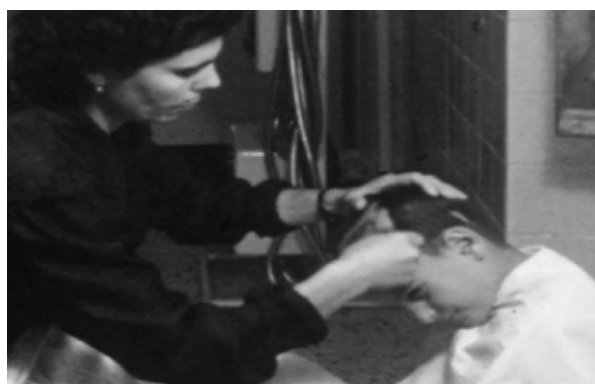

Fig. 3

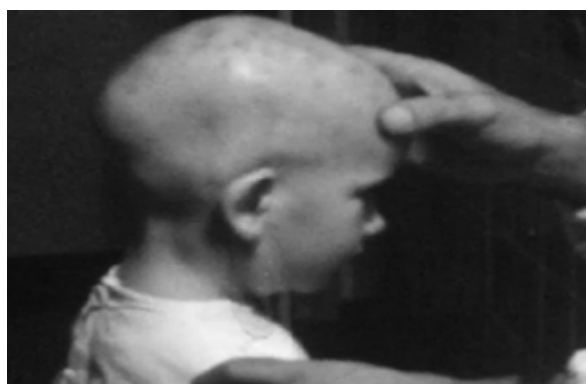

Fig. 4

Fig. 3, 4: A nurse removes the hair easily after two weeks from the irradiation (Fig. 3); in Fig. 4 you can see the post-roentgen therapy total alopecia.

and antifungal topical therapies were practiced; healing was definitive in the majority of cases.

Around the world until the '50s lacked the awareness of the risk that the radiation therapy involved, so much so that in May 1928 Wilhelm, at the annual session of Dermatology and Syphilology California Medical Association (27) emphasized the enormous progress achieved by radiation therapy in dermatology and, while warning against excessive confidence in the radiation powers, considering them only part of the therapeutic treatment, he stressed the uses and possible side effects, but did not differ from therapeutic dictates proposed by Sabouraud in 1910.

Among the side effects seen in the second half of the '40s clinicians began to report rashes or inflammation of different severity of the treated area, headache and vomiting, increased body temperature, lymph node hypertrophy and attributed them to imperfections of the technique used or to excessive intensity of irradiation (18).

Yet in 1951 at the annual meeting of the California Medical Association in the session of Dermatology and Syphilology the radiotherapy technique proposed by Sabouraud was considered the choise therapy for recalcitrant forms of ringworm.

In those years, despite in the London scientific community some doubts rose about the radiation therapy and testing of new fungicides able to eradicate the disease was wished (12), in the US, where in the big cities the influx of migrants from worldwide continued, tinea capitis was still considered a real public health problem (23). As prophylactic measures the early diagnosis and treatment, to be achieved with the help of radiation therapy, a better knowledge and training of health personnel and the segregation of affected children were proposed (10).

Even in Belfast (16) small outbreaks occurred in the pediatric population under 14 years of age, mostly treated with radiation therapy; a contraindication to radiation therapy was considered only adolescence, where notoriously the fungal infection underwent a spontaneous remission.

A breakthrough in the treatment of ringworm occurred with the discovery of griseofulvin, a drug belonging to the class of benzofurans. In 1958 griseofulvin was successfully tested by

Gentles, of the Glasgow University, orally, in treatment of mycoses in experimental animals and some months later by other researchers in the systemic treatment of human fungal infections (25). The drug works by selectively accumulating in keratin and preventing the invasion of the fungus and its replication, with a direct action carried out on the synthesis of fungal cell wall and its duplication (17). The use of griseofulvin, today assumed successfully at a dose of 15-25 mg / kg of body weight, radically changed the approach to the therapy of tinea capitis, marking the end of the radiant treatment for this disease.

This also happened because the first reports on the possible relationship between head and neck tumors and radiation therapy for ringworm began to appear (23); tumors, which were manifested even after 30-50 years of exposure, were mainly basal cell carcinomas of the skin (3), carcinomas of the thyroid and salivary glands (8), meningiomas and malignant tumors of the CNS (9).

The risk was directly related to the dose of X-rays and inversely to patient age. In the late 60ies the occurrence of malignancies in adults who had received as children irradiation of the head was unequivocally confirmed highlighting the dramatic consequences of a therapy performed unknowingly between 1910 and 1950 on about 200,000 children (6) of needy populations for an altogether benign disease.

Address to:
Dr. Maria Francesca Vardeu
Via Caprera, 38
09123 Cagliari, Italy
e-mail: francesca.vardeu@gmail.com

References

- 1) Adamson, H. G. - A simplified method of x-ray application for the cure of ringworm of the scalp: Kienbock method. *Lancet* 1, 1378-80, 1909.
- 2) BMJ - The progress of elettrotherapeutics. *Br. Med. J.* Oct 14, 935-936, 1911.
- 3) Bonaventura P., Oliveira R., Pereira D. et Al. - Head and neck basal cell carcinoma prevalence in individuals submitted to childhood X-ray epilation for tinea capitis treatment. *Eur. J. Dermatol.* 22, 225-30, 2012.
- 4) Casal M., Linares M.J., Fernandez J.C., Solis F. - Dermatophytes and Dermatophytosis in Cordoba (Spain) *Enferm. Infect. Microbiol. Clin.* 9, 491-4, 1991.
- 5) Chardonneau P., Raguet D.F. - Epilation of tinea by thallium acetate. *Maroc. Med.* 35, 961-3, 1956.
- 6) Cipollaro A.C., Kallos, A., Ruppe, J.P.Jr. - Measurement of gonadal radiations during treatment for tinea capitis. *New York J. Med.* 59, 3033-40, 1959.
- 7) Dowling G.B. - Ringworm of the scalp treated by thallium acetate epilation. *Proc. R. Soc. Med.* 20, 1055-6, 1927.
- 8) Dreyer R. A., Friedlander E. - Identifying the health risks from very low-dose sparsely ionizing radiation. *Am. J. Public Health* 72, 585-8, 1982.
- 9) Gosztonyi G., Slowik F, Pásztor E. - Intracranial meningiomas developing at long intervals following low-dose X-ray irradiation of the head. *J Neurooncol.* 70, 59-65, 2004.
- 10) Lee R.K.C. - Epidemic tinea capitis: a public health problem. *Yale J. Biol. Med.* 19, 547-555, 1947.
- 11) L'Unione Sarda, - Istituto Radioterapico annesso alla Clinica Dermosifilopatica, Cronaca Cittadina 25.02.1916.
- 12) Lydon F.L., Stefanides, T., Robb T.M. - Ringworm of the scalp. Treatment by X-Ray epilation without subsequent local application. *Br. Med. J.* March 26, 523, 1949.
- 13) Macleod J.M. - The treatment of ringworm of the scalp by the x rays. *Br. Med. J.* 2, 13-5, 1905.
- 14) Macleod J.M. - Further remarks on the treatment of ringworm of the scalp by the x rays. *B. Med. J.* 2, 619-20, 1905.
- 15) Macleod J.M. - Alopecia areata following small-spored ringworm of the scalp, *Proc. R. Soc. Med.* 1 (Dermatol. Sect.) 89, 1908.
- 16) Martin Beare J., Cheeseman E.A. - A localized outbreak of tinea capitis (M. Audouini) in Northern Ireland. *Arch. Dis. Child.* 26, 149-57, 1951.
- 17) Mondello F. - Funghi patogeni per l'uomo: generalità e prospettive. *Rapporti ISTISAN* 08/10 iii, 51, 2008.
- 18) Mottram M.E., Hill H.A. - Radiation therapy of Ringworm of the scalp, *Calif. Med.* 70, 189-93, 1949.
- 19) Sabouraud R., Noiré H. - Traitement des teignes tondantes par les rayons X. *La Presse medicale* 12, 825-7, 1904.
- 20) Sabouraud R. - Sur la radiothérapie des teignes, *Ann. Dermatol. Venereol.* 5, 577-87, 1904.
- 21) Sabouraud R. - Maladies du cuir chevelu. III. Maladies cryptogamiques. Les teignes, Masson et Cie, Paris, 1910.
- 22) Sadetzki S., Chetrit A., Freedman L. - Long-term follow-up for brain tumor development after childhood exposure to ionizing radiation for tinea capitis. *Radiat. Res.* 163, 424-32, 2005.
- 23) Shvarts S., Romem P., Romem Y., Shani M. - The mass campaign to eradicate ringworm among the Jewish community in Eastern Europe, 1921-1938. *Am. J. Public Health.* 103, e56-66, 2013.
- 24) Shore R.E., Moseson M., Xue X. et Al. - Skin cancer after X-ray treatment for scalp ringworm. *Radiat. Res.* 157, 410-8, 2002.
- 25) Steffen C., Dupree M.T. - The Introduction of Griseofulvin, *Skinmed* 3, 105-6, 2004.
- 26) Vardeu M.F., Pau M. - Pino Pinetti e il video della terapia della micosi nel nuovo Istituto Fotoradioterapico di Cagliari, 1930-1931. *Atti Giornate di Museologia Medica Quaderno* 5, 107-11, 2016.
- 27) Wilhelm L.F.X. - X-ray therapy in dermatology. *Cal. West Med.* 29, 381-4, 1928.