

*Common wart / Solitary papular angiokeratoma.* 196

*Nodular scabies.* 199

*Spitz-Reed nevus in children.* 202

*Two neonates with annular lesions of the face.* 209

*Pyogenic granuloma and timolol in a child.* 213

*Waardenburg syndrome type I.* 216

*A 13-year-old patient with psoriasis and vitiligo treated with etanercept.* 220

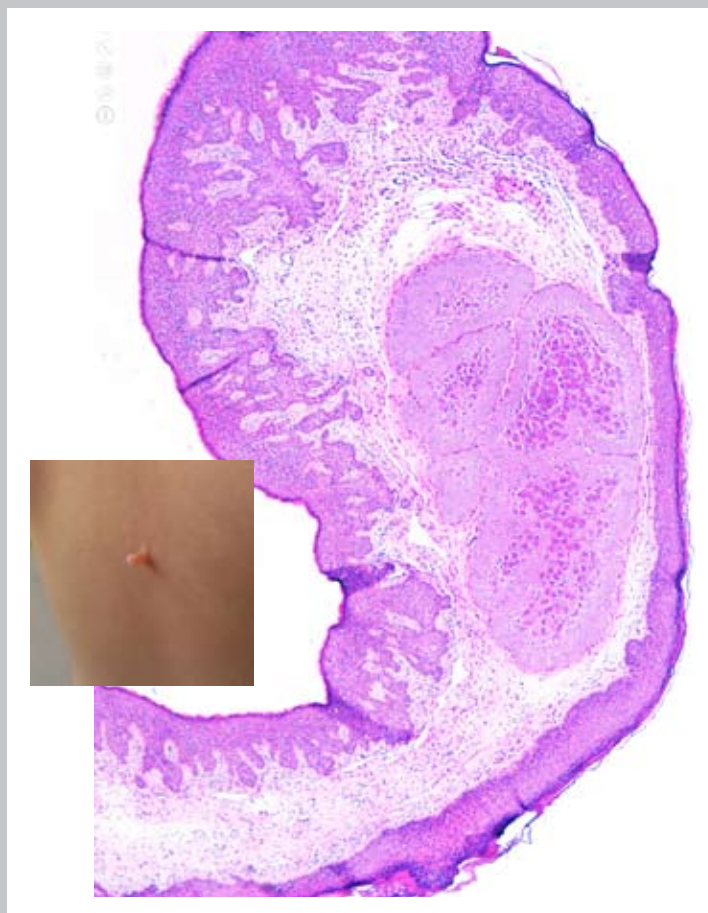
*Familial aplasia cutis.* 239

*Linear palmar and plantar melanocytic nevi.* 240

*Congenital smooth muscle hamartoma.* 241

*Fascicular pseudomelanoma on scar due to removal of congenital nevus.* 242

*Desmoplastic nevus on giant nevus spilus.* 244



*Halo Mongolian spot.* 245

*Mistreated Becker's nevus.* 246

*Molluscum contagiosum inside fibrous papilloma.* 247

*Molluscum contagiosum with unexpected outcome.* 248

*Swimming pool dermatitis of the fingertips.* 249

*Photodermatitis due to irradiation for neonatal jaundice in newborn with congenital ichthyosis.* 250

*Dermographic mastocytosis.* 251

*Scleroderma with tongue involvement.* 252

*Eosinophilic granuloma of the skin.* 253

*Peroneal pads.* 254

*Angiolymphoid hyperplasia with eosinophilia.* 256